

Received: 2022.06.21

Accepted: 2022.08.31

Available online: 2022.09.23

Published: 2022.11.02

Spontaneous Oropharyngeal Hemorrhage Complicated by Cirrhosis, Resulting in Hemorrhagic Shock

Authors' Contribution:

Study Design A
Data Collection B
Statistical Analysis C
Data Interpretation D
Manuscript Preparation E
Literature Search F
Funds Collection G

EF 1 **Dung V. Nguyen**
EF 2 **Dena H. Tran**
E 2 **Kathryn G. Champ**
E 2 **Swetha Vutukuri**
E 3 **Avelino C. Verceles**

1 Department of Internal Medicine, American University of Antigua College of Medicine, Osbourn, Antigua and Barbuda
2 Department of Internal Medicine, University of Maryland Medical Center Midtown Campus, Baltimore, MD, USA
3 Division of Pulmonary and Critical Care Medicine, University of Maryland School of Medicine, Baltimore, MD, USA

Corresponding Author: Dena H. Tran, e-mail: dena.tran@som.umaryland.edu

Financial support: None declared

Conflict of interest: None declared

Patient: **Male, 54-year-old**
Final Diagnosis: **Hemorrhagic shock**
Symptoms: **Altered mental status**
Medication: —
Clinical Procedure: —
Specialty: **Critical Care Medicine**

Objective: **Unusual clinical course**

Background: Spontaneous oropharyngeal hemorrhage is rare and is often associated with other predisposing factors. This can result in hemodynamic instability in the presence of other bleeding sources. It is oftentimes difficult to diagnose due to its limitations to visual inspection of the oropharyngeal structures. It is commonly mistaken for hemoptysis or hematemesis upon initial evaluation. Trauma, infection, pulmonary pathologies (ie, lung cancer or tuberculosis), gastrointestinal pathologies (ie, esophageal/gastric varices, Mallory-Weiss tears, esophagitis), coagulopathies, medications, and prolonged intubation have been shown to increase the risk of oropharyngeal hemorrhage.

Case Report: A 54-year-old man with a medical history of alcohol use disorder, liver cirrhosis, portal hypertension, and gastric varices presented with altered mental status. He was subsequently intubated for airway protection. Bleeding from the oropharynx was later found. Esophagogastroduodenoscopy (EGD) and bronchoscopy were unrevealing. Computed tomography angiography (CTA) of the head and neck revealed active bleeding of the right posterior pharyngeal artery, which was emergently embolized. Over the next few days, he continued to bleed from the oropharynx and became hemodynamically unstable. CTA abdomen showed bleeding from gastric varices and large-volume hemoperitoneum with multiple sources of active bleeding from the liver, duodenum, and jejunum.

Conclusions: We present a rare case of spontaneous oropharyngeal hemorrhage and gastric variceal bleeding resulting in hemorrhagic shock in a cirrhotic patient with multiple predisposing factors. If a patient presents with spontaneous oropharyngeal hemorrhage, clinicians should consider bleeding from the oropharynx if EGD and bronchoscopy are unrevealing. Thus, an emergent CTA of the head and neck should be strongly considered to further evaluate a potential source of active bleeding, as delayed diagnosis can be life-threatening.

Keywords: **Hemorrhagic Shock and Encephalopathy Syndrome • Liver Cirrhosis • Liver Cirrhosis, Alcoholic • Hepatic Encephalopathy • Esophageal and Gastric Varices**

Full-text PDF: <https://www.amjcaserep.com/abstract/index/idArt/937582>



1749



—



1



6

Background

Spontaneous oropharyngeal hemorrhage is rare and is often associated with other predisposing factors. This can result in hemodynamic instability in the presence of other bleeding sources. Oropharyngeal hemorrhage is oftentimes difficult to diagnose due to the limitations in visual inspection of the oropharyngeal structures and is commonly initially mistaken for hemoptysis or hematemesis. Therefore, early diagnosis of severe bleeding from the oropharyngeal cavity can be delayed, resulting in increased mortality [1].

There have been limited case reports demonstrating bleeding from the base of the tongue and the epiglottic vallecula, both of which occurred in the setting of chronic liver disease with portal hypertension, although the pathogenesis of these occurrences is still poorly understood [1,2]. Prior studies have shown that spontaneous oropharyngeal hemorrhage typically results from trauma, infection, pulmonary pathologies (such as lung cancer or tuberculosis), and gastrointestinal pathologies (such as esophageal/gastric varices, Mallory-Weiss tears, or esophagitis) [1,3,4]. Intubated patients with certain risk factors such as being on anticoagulation, coagulopathies secondary to underlying disease, and a history of prolonged intubation have increased risk for oropharyngeal hemorrhage as well [1].

Given the limited case reports regarding oropharyngeal hemorrhage in the medical literature, we present one of the first documented cases of oropharyngeal hemorrhage and gastric variceal bleeding, resulting in significant blood loss and hemorrhagic shock.

Case Report

A 54-year-old man presented to the Emergency Department (ED) with altered mental status. His medical history was significant for alcohol use, liver cirrhosis, portal hypertension, chronic pancreatitis, substance use (on suboxone therapy), and multiple previous hospitalizations for hepatic encephalopathy. He drank approximately half a pint of vodka and a 12-ounce can of beer daily. His last drink was 1 day prior to presentation.

In the ED, his vitals were temperature 36.8°C, heart rate 120 beats per minute, blood pressure 124/87 mmHg, respiratory rate 18 breaths/minute, and oxygen saturation 95% on room air. The patient was ill-appearing, somnolent, oriented to person and place, and answered questions appropriately. The sclera was icteric, skin was jaundiced, and abdomen was soft, and nontender, but was distended with notable purplish bruising on the left flank and epigastrium, concerning for Cullen and Grey-Turners sign. Initial complete blood count (CBC) and comprehensive metabolic panel (CMP) in the ED revealed a

hemoglobin level of 10.9 g/dL, platelet level of 45 000 platelets/millimeter³, blood urea nitrogen (BUN) level of 5 mg/dL, and a creatinine level of 0.84 mg/dL. Coagulation studies revealed an International Normalized Ratio (INR) of 1.77, partial thromboplastin time (PTT) of 41.9 seconds, and fibrinogen level of 147 mg/dL. Urine toxicology revealed alcohol level 113. The patient was given 1 liter of Lactated Ringers, 50 milligrams (mg) of chlordiazepoxide, 6 mg of lorazepam, 2 grams of magnesium sulfate, and 100 mg of thiamine. He became hypoxic, requiring 4 liters of nasal cannula, and later required intubation for airway protection due to worsening mental status. He was admitted to the Intensive Care Unit (ICU) for high suspicion of acute-on-chronic liver failure complicated by hepatic encephalopathy and alcohol withdrawal syndrome.

On the second day of ICU admission, he was noted to have 5-10 milliliters (ml) of bright red blood hematemesis. Continuous nasogastric suctioning revealed approximately 400-500 ml of bright red blood. Laboratory findings revealed a decreased hemoglobin to 9.4 from 10.9 g/dL, platelet count stable at 40 000-45 000 platelets/millimeter³, increased INR to 2.15 from 1.77, increased PTT to 43.4 from 41.9, and increased fibrinogen level to 177.0 from 147.0. Given his significant history of liver disease, there was a concern for a variceal bleed. An emergent bedside esophagogastroduodenoscopy (EGD) was performed, which showed a blue-colored, enlarged, tortuous, isolated gastric varix type 1 (IGV-1) along the cardia and greater curvature of the stomach, with no red wale sign. The rest of the EGD findings were unrevealing for any active esophageal or gastric variceal bleeds. Subsequent bedside bronchoscopy also failed to reveal a source of active bleeding. The patient was noted to continuously bleed from the oropharynx, but no active source of bleeding was identified. As a temporizing measure, nasal packing was placed into each nare. Computed tomography angiography (CTA) of the head and neck revealed active bleeding of the right posterior pharyngeal artery (**Figure 1**), which was then emergently embolized using glue by interventional radiology.

The following day, he continued to bleed from the oropharynx. His hemoglobin decreased from 8.8 mg/dL to 7.4 mg/dL and INR increased from 1.67 to 2.03; platelet count remained stable at 50 000-60 000 platelets/millimeter³. He was transfused with 1 unit of packed red blood cells (PRBC) and 1 unit of fresh frozen plasma (FFP) to correct the hemoglobin level and coagulopathy. He became hemodynamically unstable, requiring vasopressors. He subsequently was taken to the operating room with otolaryngology (ENT) for an esophagoscopy, which showed no active nasal or oropharyngeal bleeding. However, there was a concern that the source of active bleeding was from the stomach. Computed tomography angiography (CTA) abdomen showed active bleeding from the gastric varix along the fundus of the stomach. A plug-assisted retrograde transvenous obliteration (PARTO) procedure was attempted by the gastroenterologist,

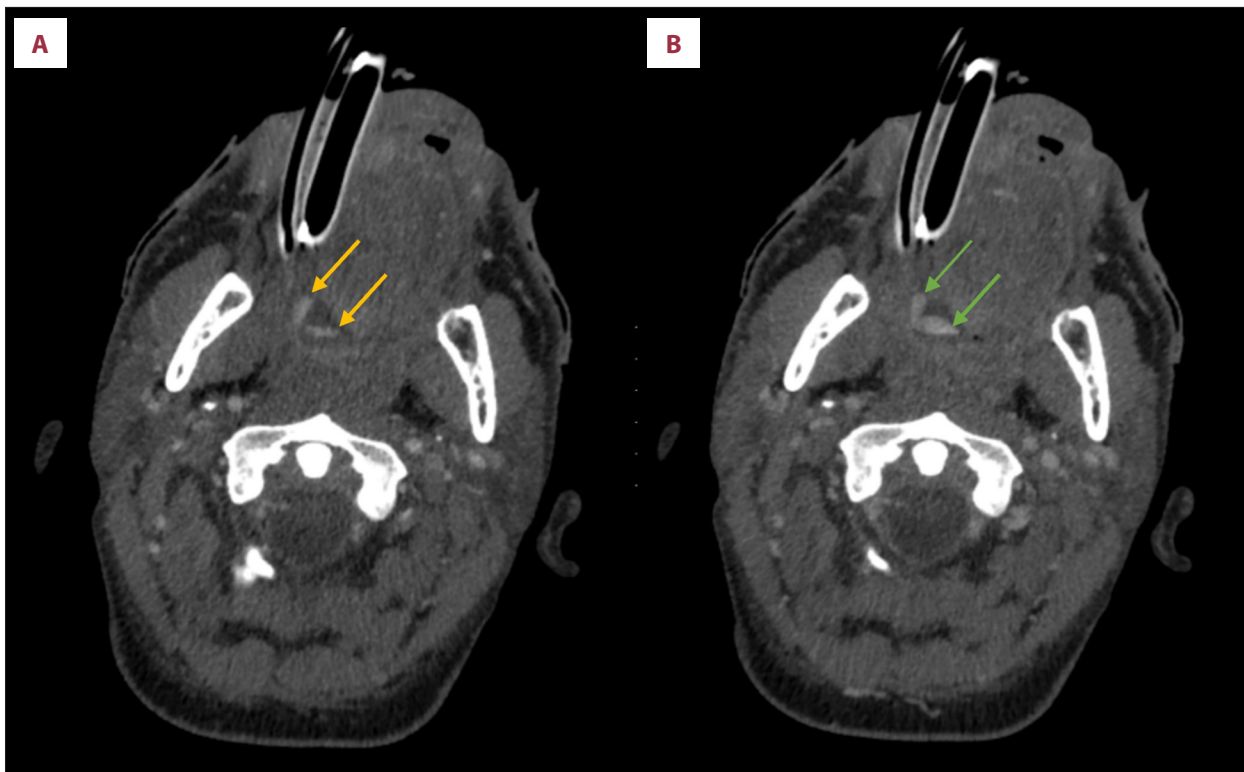


Figure 1. Oropharyngeal hemorrhage demonstrated on CTA head and neck. (A) Arterial phase, showing 2 foci of contrast blush involving the right lateral tongue (yellow arrows). (B) Portal venous phase, showing foci of contrast blush have expanded, suggesting active bleeding with venous pooling (green arrows).

but the procedure was aborted due further hemodynamic instability. Octreotide and omeprazole infusions were initiated after the procedure prior to transjugular intrahepatic portosystemic shunt (TIPS). It was noted that there was gastric variceal sclerosis, and embolization along with TIPS revision was performed by interventional radiology. During the procedure, the patient was found to have bloody output from the orogastric tube and the oral cavity, requiring 3 units of PRBCs and 2 units of FFP. He was transferred back to the ICU for further management.

He remained hemodynamically unstable, with a decline in hemoglobin and platelets. Due to the concern for an intra-abdominal source of bleeding, a computed tomography angiography (CTA) abdomen/pelvis was performed, which showed large-volume hemoperitoneum with multiple sources of active bleeding from the liver, duodenum, and jejunum. The multidisciplinary team gathered and discussed the situation with his family, leading to the decision to transition to comfort care given the patient's poor prognosis, and he was compassionately extubated.

Discussions

Spontaneous oropharyngeal hemorrhage is an uncommon presentation. Potential etiologies include, but are not limited to,

trauma, infections (such as tuberculosis and fungal infections), oropharyngeal varices, lung cancer, esophageal/gastric varices, Mallory-Weiss tears, esophagitis, coagulopathies, and medications [1,3-6]. An intubated patient presenting with blood in the mouth without an obvious source can be difficult to diagnose since the etiology could be upper airway, pulmonary, or gastroesophageal. Therefore, it is crucial to have a very detailed history to distinguish the likely anatomical source of bleeding as well as the cause of the bleeding. Hemoptysis is often associated with cough with or without frothy sputum and a history of lung disease, whereas hematemesis tends to present more frequently with frank blood or coffee-grounds emesis, a history of gastroesophageal disease, and frequent episodes of retching/vomiting. Due to the acute nature of this bleeding, the presence of drug-drug interactions (such as co-administration of warfarin and antifungals or other CYP450-inhibiting medications) was considered, as it is a potential risk factor for acute bleeding. Given the patient's history of medication non-adherence, this was lower in the differential diagnoses. Our patient also presented with laboratory findings suggestive of an underlying coagulopathy, which can pose an additional risk for acute bleeding. Given this patient's long history of cirrhosis, this was most likely one of the predisposing factors, which led to an acute oropharyngeal bleed and hemorrhagic diathesis,

Nasal or anterior oral bleeds are usually apparent on physical assessment. Oropharyngeal bleeds, such as in this case, however, present a particular diagnostic challenge, as it was not readily identified upon first attempt. Additionally, this patient was unable to provide a history to guide our intervention, resulting in further delay in diagnosis of the bleed. However, from physical assessment, the onset of the oropharyngeal bleed was noted to have occurred after intubation, which narrowed the differential diagnosis. Intubated patients have higher risks for oropharyngeal hemorrhage secondary to being on anticoagulation, having an underlying coagulopathy (such as from cirrhosis), and a history of prolonged intubation [1]. Being intubated creates a unique risk of oropharyngeal bleeding resulting from mechanical device-induced pressure ulcers (secondary to prolonged periods of intubation) and iatrogenic trauma from endotracheal tube manipulation during the care of the patient [1]. These oropharyngeal bleeds are usually non-fatal and are usually adequately controlled and managed. Oropharyngeal bleeding can also present with hematemesis, hemoptysis, melena, or a combination of the three. Evaluation of oropharyngeal bleeding should include the criterion standard of laryngoscopy and may also include esophagogastroduodenoscopy (EGD) or CTA.

Cirrhosis predisposes multiple risk factors for bleeding diathesis, such as thrombocytopenia, coagulopathy, and the development of varices secondary to portal hypertension. Typically, having thrombocytopenia with platelet levels less than 20 000 is worrisome due to severe risk for acute bleeding. Although the patient had baseline thrombocytopenia with levels greater than 20 000; having lower platelets still increases the propensity for acute bleeding. Furthermore, the patient's baseline coagulopathy secondary to impaired clotting factor synthesis from cirrhosis along with varices from portal hypertension also creates additional risk for acute bleeding. The increased portal

pressures from cirrhosis predispose to risk of varices, such as gastroesophageal varices, oropharyngeal varices, tongue base varices, and epiglottic vallecula varices, all of which can create a severe hemodynamic burden [5,6]. Given this patient's history of liver disease, underlying varices was also high on the differential diagnosis. This patient was found to have a gastric varix, which eventually bled. With the patient subsequently having a poor predicted survival based on various scoring systems (Maddrey discrimination function score [MDF]=69.4 points and MELD-Na score=22 points), the complications from cirrhosis were most likely the main stressor for hemorrhagic shock. The cumulating complications from cirrhosis with subsequent hypovolemia from gastric bleeding and the complications that come with being treated in the ICU, the addition of an acute bleed, such as from an oropharyngeal bleed, was enough to cause the patient to become hemodynamically unstable and go into shock.

Conclusions

Dramatic hemodynamic changes are rare in oropharyngeal bleeding but can occur in association with other comorbidities. If a patient presents with spontaneous oropharyngeal hemorrhage, clinicians should quickly consider bleeding from the oropharynx if EGD and bronchoscopy are unrevealing. Thus, an emergent CTA of the head and neck should strongly be considered to further evaluate a potential source of active bleeding, as a delayed diagnosis can be life-threatening.

Declaration of Figures' Authenticity

All figures submitted have been created by the authors who confirm that the images are original with no duplication and have not been previously published in whole or in part.

References:

1. Mulcahy CF, Ghulam-Smith M, Mamidi IS, et al. Oropharyngeal hemorrhage in patients with COVID-19: A multi-institutional case series. *Am J Otolaryngol.* 2020;41(6):102691
2. Polacco M, Ossoff J, Paydarfar J. Vallecular varix: A perplexing cause of oral cavity bleeding. *Western J Emerg Med.* 2015;16(7):1201-2
3. Earwood JS, Thompson TD. Hemoptysis: Evaluation and management. *Am Fam Physician.* 2015;91(4):243-49
4. Kamboj AK, Hoversten P, Leggett CL. Upper gastrointestinal bleeding: Etiologies and management. *Mayo Clin Proc.* 2019;94(4):697-703
5. T Kim Y-M, Kim JW, Park IS, et al. Tongue base varix as a source of oral bleeding. *Medicine.* 2019;98(42):e16987
6. Laghari MH, Byrne MF, Chatur N, et al. A bleeding vallecular varix, visualized by GI endoscopy, confirmed with CT angiography, and treated with sclerotherapy and cyanoacrylate. *VideoGIE.* 2017;3(1):20-22